

15 Verzini F, Parlani G, Romano L, De Rango P, Panuccio G, Cao P. Endovascular treatment of iliac aneurysm: concurrent comparison

of side branch endograft versus hypogastric exclusion. *J Vasc Surg* 2009;49:1154–61.

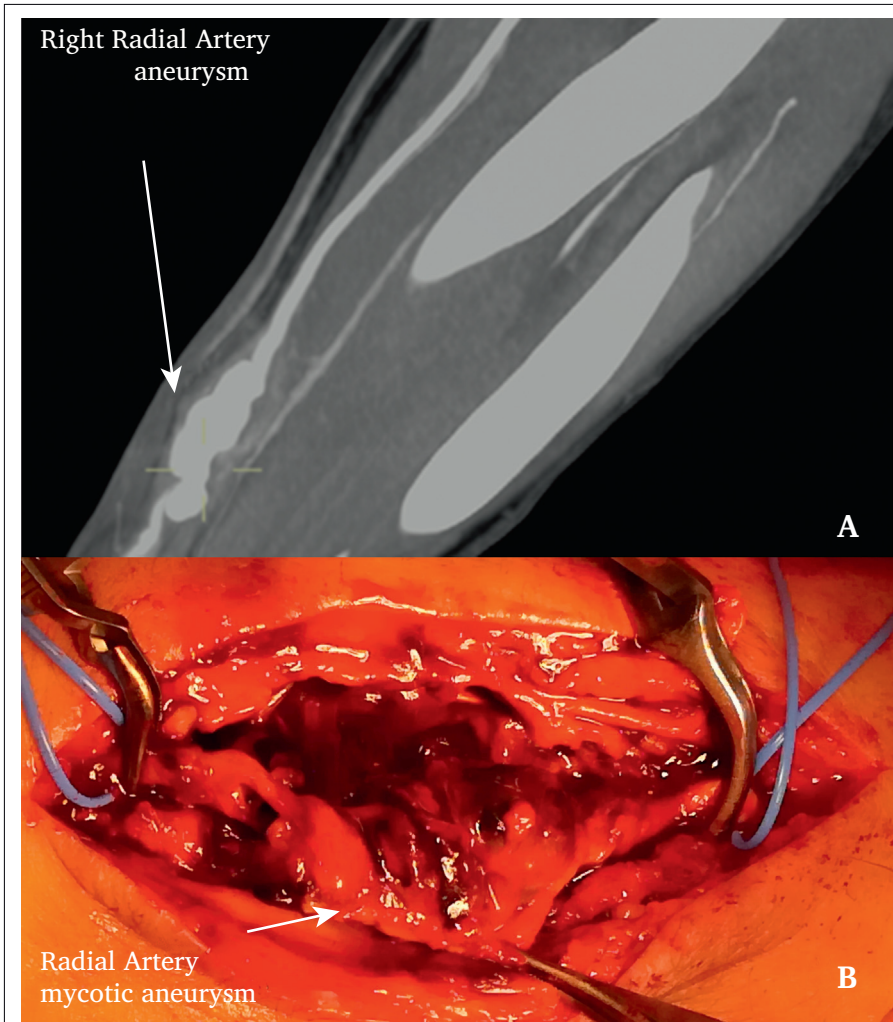
Eur J Vasc Endovasc Surg (2019) 58, 838

COUP D'OEIL

Radial Artery Mycotic Aneurysm

Buitron Gabriel^{*}, Kuzniar Marek

Department of Surgical Sciences, Vascular Surgery, Uppsala University, Uppsala, Sweden



A 75-year-old male with diabetes type II and ischemic heart disease presented to the emergency department with a painful mass in the right wrist. He had a history of coronary angiogram performed 26 days earlier. A pulsatile reddened mass was identified on examination. His blood samples showed raised inflammatory parameters. CT scan revealed a distal right radial artery multilobular aneurysm (Panel A). Due to suspected mycotic aneurysm, the patient underwent surgical exploration (B), with ligation of the right radial artery after confirmation of a negative Barbeau test. Positive cultures for *Pseudomonas aeruginosa* in wound and blood were found.

^{*} Corresponding author.

E-mail address: gbuitronp87@hotmail.com (Buitron Gabriel).

1078-5884/© 2019 European Society for Vascular Surgery. Published by Elsevier B.V. All rights reserved.

<https://doi.org/10.1016/j.ejvs.2019.07.031>